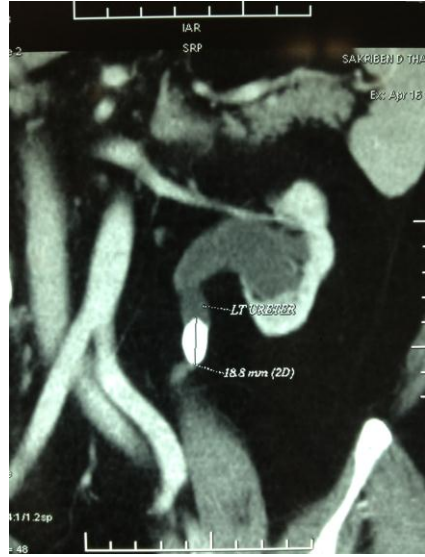
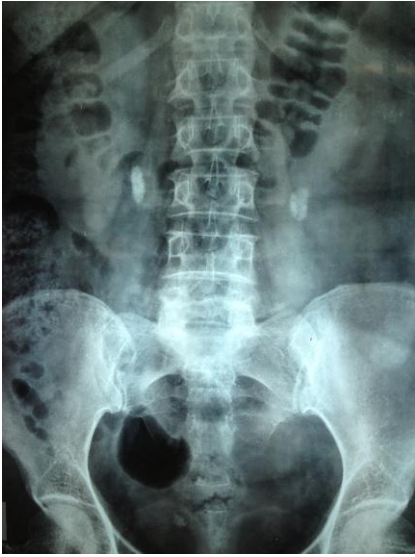

## CASE OF B/L UPPER URETERIC CALCULUS + RT LOWER URETERIC CALCULUS

A Female patient aged 60yrs having following details.

- Complain: Pain at right renal angle since 20 days.  
Off & on pain at left side  
Nausea associated  
Burning in Urine
- Advised : X-Ray (KUB)  
Pre Op Minor  
CT IVP
- Diagnosis : X-ray KUB shows B/L Ureteric calculus  
Right lower ureteric calculus
- Surgical Plan : Bilateral PCNL + URS



Bilateral Upper ureteric calculus



